

(CASE REPORT)



## Carcinoma of bladder: A rare case report

P. Naga Jyothi \*, G. Sreemahalaksmi, G. Sai Prathyusha and M. Swapna

*Department of pharmacy practice, Santhiram College of pharmacy, Nandyal, Andhra Pradesh, India.*

World Journal of Biology Pharmacy and Health Sciences, 2023, 13(01), 272–276

Publication history: Received on 27 November 2022; revised on 10 January 2023; accepted on 13 January 2023

Article DOI: <https://doi.org/10.30574/wjbphs.2023.13.1.0017>

### Abstract

Bladder cancer begins after the healthy cells in the bladder wall, the most commonly urothelial cells change and grow out of control, forming a mass called tumor urothelial cells, the urothelial cells that also line the renal pelvis and ureter cancer that develops in the type of urothelial cancer, and it is often called upper tract urothelial cancer. A tumor can be benign or malignant, a cancerous tumor is malignant it can grow and spread to other parts of the body, a benign tumor means the tumor can grow but will not spread, these are very rare. Bladder tumors can be divided into 3 types based on microscopic structure of the tumor cells: Urothelial carcinoma, squamous cell carcinoma, adenocarcinoma and others include sarcoma. These cancers may be of two types based on cell type bladder cancer that can be categorized as NMIBC (Non-muscle invasive bladder cancer) and MIBC (Muscle invasive bladder cancer). Risk factors include tobacco use, age, gender, race, chemicals, chronic bladder problems, cyclophosphamide use and pioglitazone use, personal history, schistosomiasis, arsenic exposure, genetic syndromes. Clinical symptoms are blood clots in the urine, pain or burning micturition, frequent urination, lower back ache on one side of the body in the abdomen region, hematuria. Diagnostic tests include urine test, cystoscopy, biopsy, TURBT, MRI, CT (KUB), and USG. Treatment includes surgical removal by TURBT, BCG vaccination, radiotherapy, chemotherapy, and immunotherapy in addition palliative or supportive care.

**Keywords:** Bladder cancer; Cystoscopy; Urothelial cancer; TURBT; BCG; NMIBC; MIBC

### 1. Introduction

Carcinoma of the bladder is a condition characterized by the abnormal growth of bladder tissue. It is known that the tumor that develops in the bladder lining in some cases may also spread to bladder muscle. Bladder cancer<sup>1-3</sup> is more common in Caucasians, it typically affects elder patients in the median age of 73 years and males are more prone to bladder tumor than females.<sup>4</sup>

#### 1.1. Types of bladder cancer

Bladder tumors can be divided into 3 types based on microscopic structure of the tumor cells:<sup>5</sup>

- Urothelial carcinoma
- Squamous cell carcinoma
- Adenocarcinoma
- Others include sarcoma.

The staging of the bladder tumor was done based on the layers of urinary bladder from inner to outer and that includes, Transitional epithelium

\* Corresponding author: P. Naga Jyothi

- Sub-mucosa or lamina propria
- Muscularis
- Serosa/adventitia.

The bladder cancer is commonly staged using the American Joint Committee on Cancer (AJCC) TNM imaging system.<sup>6</sup>

**Signs and symptoms include** Pelvic pain, bone pain, unintentional weight loss, kidney infection, renal calculus, urinary tract infections, cystitis, urethritis, enlarged prostate gland (BPH) in men.

## 1.2. Causes

### 1.2.1. Smoking

Smoking is the main cause for bladder tumor because tobacco contains carcinogenic chemicals, that pass through the blood stream and filtered by the kidneys that can cause changes to the cells of bladder lining, smokers may be up to 4 times more likely to develop bladder tumor than non-smokers.<sup>4,7</sup>

### 1.2.2. Prostate enlargement

If the prostate is enlarged, it can cause a pressure on the urethra that may lead to disruption in flow, leaving some urine in the bladder.

### 1.2.3. Bladder inflammation

Infections like UTI or radiation therapy can cause the bladder to enlarge.

### 1.2.4. Kidney stones

kidney stones can migrate down to the ureters if too large to pass that will remain in the bladder and cause bladder obstruction that are more commonly bladder stones increase the risk for carcinoma of bladder.

Bladder diverticula: Pouches can form within the bladder that grow large in size, they can hold the urine and prevent the bladder from being emptied.

Cystocele: In women the bladder wall can become weak and drop down to the vagina this can affect the flow of urine from the bladder.

## 1.3. Risk factors

### 1.3.1. Age and gender

Bladder tumor is more common in males above 50 years of age compared to females.

### 1.3.2. Bladder outlet obstruction

Any condition that blocks the flow of urine from the bladder to outside world. For example, the most common is enlarged prostate.

Chemicals known to increase the risk of bladder cancer include Aniline dyes, 2-Naphthylamine, 4-Aminobiphenyl, Xenylamine, benzidine, o-toluidine.

Occupations linked to an increased risk of bladder cancer are manufacturing jobs involving dyes, textiles, rubbers, paints, plastics, leather tanning.

Some non-manufacturing jobs have also been linked to an increased risk of bladder cancer. These include taxi or bus drivers, because of their regular exposure to the chemicals present in diesel fumes.

### 1.3.3. Social habits

Smoking and alcohol use may increase the risk of bladder cancer.<sup>7</sup>

Other factors that can increase your risk of bladder cancer include:

- Radiotherapy to treat previous cancers near the bladder, such as bowel cancer
- Previous treatment with certain chemotherapy medications, such as cyclophosphamide and cisplatin
- Having diabetes – bladder cancer is thought to be linked to certain treatments for type 2 diabetes like pioglitazone an oral hypoglycemic drug
- Having a tube in your bladder (an indwelling catheter) for a long time, because you have nerve damage that has resulted in paralysis
- Long-term or repeated urinary tract infections (UTIs)
- Long-term bladder stones
- Having an early menopause (before the age of 45)
- An untreated infection called schistosomiasis, which is caused by a parasite that lives in fresh water – this is very rare in the UK
- Singular inheritable genetic risk factors are rare in patients with bladder or urinary tract cancer, patients with lynch syndrome that is due to defects in mismatch repair of genes (mlh1, msh2, msh6) leading to microsatellite instability, are at particular risk of upper urinary tract cancer of renal pelvis and ureter
- Patients with Cowden disease (PTEN mutations), retinoblastoma (rb1 mutation) are at increased risk of bladder tumor<sup>8</sup>

#### 1.4. Complications

Chronic bladder dysfunction: frequent urination that is painful and uncomfortable, that can completely block urine outflow from the body.

#### 1.5. Diagnosis

- Physical examination: on examination of the loin region and lower abdomen feel the bladder if enlarged
- Urine analysis: a urine sample test for signs of blood, bacteria and crystalized minerals, tumor growth
- Computerized tomography, Ultrasound, X-ray images to build up the detailed information of internal organs and the size of bladder stone or calculi
- Intravenous pyelogram: A special fluid is injected into the veins that travels to the kidney and bladder, X-rays are taken throughout the procedure to look the signs of kidney or bladder stones

#### 1.6. Management

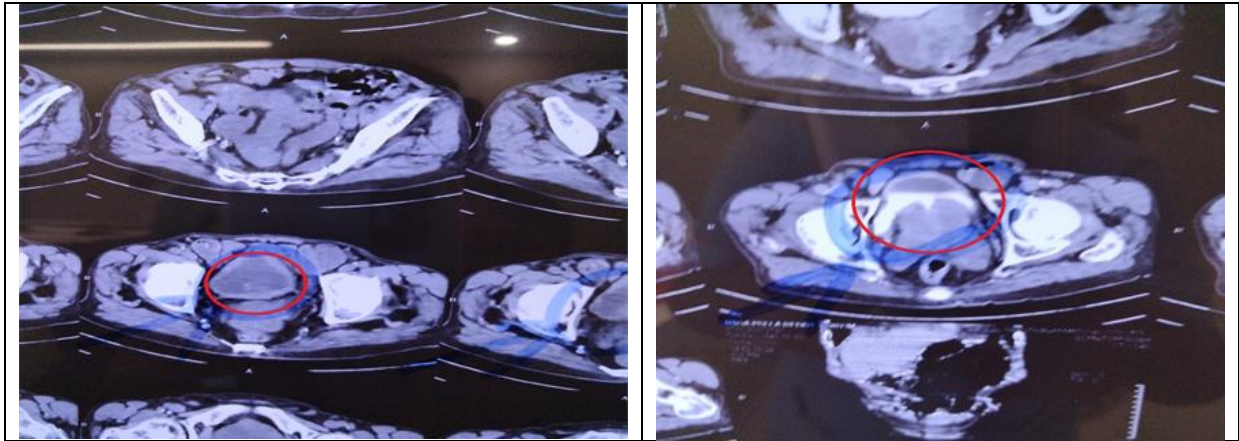
Treatment includes surgical removal by TURBT, BCG vaccination, radiotherapy, chemotherapy, and immunotherapy in addition palliative or supportive care.<sup>2</sup>

---

## 2. Case report

A male patient of 85 years was reported in urology department with a chief complaint of hematuria in the past 1 month, patient was apparently normal one month back and then had a history of poor urinary stream, urine urgency, and history of lower abdominal pain. The patient had a history of hypertension since 2 years on regular treatment with T. Amlodipine (5 mg) + Atenolol (50 mg). The patient was advised with some lab investigations it reveals as follows: CT KUB-markedly enlarged prostate with median lobe hypertrophy protruding into bladder-benign prostatic hyperplasia, diffuse bladder wall thickening with mucosal irregularity-cystitis, malignant lesion in posterior wall of bladder, non-obstructive right renal calculus, serum electrolytes (serum sodium-135 mmol/lit, serum potassium-4.6mmol/lit, serum chloride-104mmol/lit) Prothrombin time-24sec, INR-1.7, Serum creatinine-1.2 mg/dl, RBS-89 mg/dl, Urine culture- No bacterial growth on culture, pus cells-6-8 /hpf, epithelial cells- 2-3/hpf. CBP (HB-11.3g/dl, WBC-11500 n/ul, N-55%, L-35%, M-4%, Platelet count-4.15L/cumm), Blood grouping test-B-positive. Based on the test reports the patient was advised for cystoscopy. On cystoscopy evaluation (external urethral meatus: adequate, anterior urethra: normal, posterior urethra: grade-3 lateral lobe, grade -2 median lobe/L urethric orifice seen normal, mild to moderate bladder trabeculations present with 3\*3\*2 cm growth on right inferior aspect near to bladder neck inferior to right ureteric orifice with calcification), based on subjective and objective findings the patient was diagnosed to be with carcinoma of urinary bladder or urothelial carcinoma that is formerly referred as transitional cell carcinoma, clinical stage was cT2N0M0.<sup>3</sup> Preoperative cardiac risk assessment was done before surgery reveals as low risk for surgery. Patient consent was taken, and surgical procedure was explained to the patient. Trans urethral resection bladder tumor (TURBT) was done for removal of the bladder tumor. Since this case is a type of muscle invasive bladder cancer post-operative care includes treatment with IV fluids Normal saline/DNS 120ml/hr., continuous irrigation with normal saline, Ceftriaxone injection 1.5gm/IV/OD, Tramadol injection 100 mg/IV/TID, Pantoprazole injection 40mg/IV/OD,

Ondansetron injection 4mg/IV/SOS and finally to monitor temperature, BP vitals along with urine output and input. The patient was stable after the surgery and after 3 days stopped injections and IV fluids then treated with oral tablets.



**Figure 1** Images of CT-KUB

---

### 3. Discussion

Bladder tumor is a condition characterized by the abnormal growth of tissue, known as tumor, that develops in the bladder lining. In some cases, may also spread to bladder muscle, Bladder cancer begins when healthy cells in the bladder lining the most commonly urothelial cells change and grow out of control, forming a mass called tumor urothelial cells also line the renal pelvis and ureter cancer that develops in the renal pelvis and ureters is also considered a type of urothelial cancer and it is often called upper tract urothelial cancer.

In this study we note that due to hypertension, smoking and age, gender related risk for bladder tumor. In this case the primary goal was to decrease the spread of infection and pain, achieved by surgical procedure (TURBT) along with the medical management like radiation and chemotherapy of carboplatin and gemcitabine have been used according to the standard treatment of most of the sarcomas. But the patient showed poor response to radiation therapy and hence treated with cisplatin of 35mg/m<sup>2</sup> and dexamethasone 20 mg I.V in 50 ml normal saline.

The result obtained from this study ensures that the treatment followed and after the surgical procedure for bladder tumor the complete clearance was achieved. Reduces the infection spread and may not lead to further complications.

---

### 4. Conclusion

In this study we conclude that the transurethral resection of bladder tumor (TURBT) is the most useful method for the carcinoma of bladder and bladder tumor removal, to reduce the urinary tract infection and further complications. The result showed that complete tumor clearance was achieved and further managed with medications. The patient was hemodynamically stable at the time of discharge, The patient was counselled regarding diet, medication, lifestyle modifications like: To have a lot of fruits and vegetables that provide magnesium, potassium, fiber, citric acid that reduces stone risk watermelon, papaya, and cruciferous vegetables like broccoli and cauliflower. Some organic foods like eggs and sufficient calcium are about 100 mg/day (milk, cheese). Avoid foods containing excess of oxalate (spinach, dark chocolates, black tea, sweet potato), salt-restricted diet, limit intake of proteins, drink plenty of water lemon and orange juice. Avoid stress. Review after 1 week to urology department if the symptoms persists and this study was conducted in our tertiary care teaching hospital.

---

### Compliance with ethical standards

#### *Acknowledgments*

We thank the Institute SRCP for their kind support.

#### *Disclosure of conflict of interest*

There are no conflicts to declare.

*Statement of ethical approval*

The present research work does not contain any studies performed on animals/human subjects by any of the authors.

*Statement of informed consent*

Informed consent was obtained from the individual participant included in the study.

---

**References**

- [1] Prout Jr., G. R.; Griffin, P. P.; Shipley, W. U., Bladder carcinoma as a systemic disease. *Cancer* 1979; 43 (6): 2532-9.
- [2] Flocks, R. H., TREATMENT OF PATIENTS WITH CARCINOMA OF THE BLADDER. *Journal of the American Medical Association* 1951; 145 (5): 295-301.
- [3] Wong, V. K.; Ganeshan, D.; Jensen, C. T.; Devine, C. E. Imaging and Management of Bladder Cancer *Cancers* [Online], 2021.
- [4] Jameson, J. L.; Fauci, A. S.; Kasper, D. L.; Hauser, S. L.; Longo, D. L.; Loscalzo, J., *Harrison's Principles of Internal Medicine, Twentieth Edition (Vol.1 & Vol.2)*. McGraw-Hill Education: 2018.
- [5] Young, R. H.; Eble, J. N., Unusual forms of carcinoma of the urinary bladder. *Human Pathology* 1991; 22 (10): 948-65.
- [6] Babjuk, M.; Oosterlinck, W.; Sylvester, R.; Kaasinen, E.; Böhle, A.; Palou-Redorta, J.; Rouprêt, M., EAU Guidelines on Non-Muscle-Invasive Urothelial Carcinoma of the Bladder, the 2011 Update. *European Urology* 2011; 59 (6): 997-1008.
- [7] Fleshner, N.; Garland, J.; Moadel, A.; Herr, H.; Ostroff, J.; Trambert, R.; O'Sullivan, M.; Russo, P., Influence of smoking status on the disease-related outcomes of patients with tobacco-associated superficial transitional cell carcinoma of the bladder. *Cancer* 1999; 86 (11): 2337-45.
- [8] Shokeir, A. A., Squamous cell carcinoma of the bladder: pathology, diagnosis and treatment. *BJU International* 2004; 93 (2): 216-20.