

Bowen's disease of the nail bed: A case report

Imad Bekkal * and Abdelkarim Daoudi

Traumatology and orthopedics department. Mohammed VI University Hospital of Oujda, Morocco.

World Journal of Biology Pharmacy and Health Sciences, 2023, 16(01), 147–151

Publication history: Received on 05 September 2023; revised on 15 October 2023; accepted on 17 October 2023

Article DOI: <https://doi.org/10.30574/wjbphs.2023.16.1.0434>

Abstract

We present a case of Bowen's disease of the nail bed in a 32-year-old patient admitted to the traumatology-orthopedics department for a persistent lesion of the right thumb nail. Bowen's disease is often misdiagnosed because of its benign, slowly progressive appearance. The clinical picture of this disease is not uniform and can mimic a number of other dermatological disorders, such as vulgar warts, onychomycosis and various clinical presentations. Therefore, biopsy of any chronic nail tissue lesion is essential. Surgical excision is the treatment of choice for tumours without bone involvement. Our patient was treated with Mohs micrographic surgery. Postoperatively, the patient noticed a sensation of hypoesthesia in the treated area, which regressed almost completely over the following months.

Keywords: Bowen; Nail; Diagnosis; Biopsy; Mohs

1. Introduction

Bowen's disease of the nail is a squamous cell carcinoma in situ that can progress to invasive carcinoma of the skin [1]. It mainly affects men between the ages of 40 and 70 [2]. It is the most common neoplasia of the nail [3]. Its incidence is rare or underestimated. The tumor affects the nail bed in 57% of cases, and the paronychia in 32% [3]. The disease can mimic various benign conditions such as vulgar wart or onychomycosis, and diagnosis is often delayed as the lesion evolves slowly and the appearance is misleading.

In our work, we present a case of Bowen's disease of the nail bed in a 32-year-old man treated by Mohs micrographic surgery, and we emphasize the need to perform a biopsy of any chronic lesion of the nail apparatus.

2. Case report

A 32-year-old man was admitted to the traumatology-orthopedics department with a persistent lesion of the right thumb nail. The history of symptomatology dated back 2 years when the patient presented with a verrucous lesion of the right thumb medial border progressively increasing in size (figure 1).

* Corresponding author: Bekkal Imad

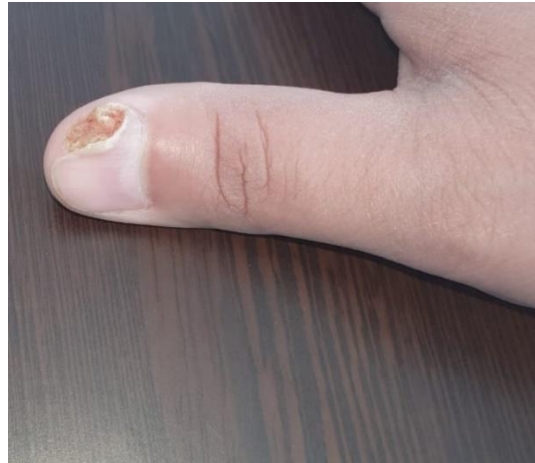

Figure 1 Verrucous lesion on the medial border of the right thumb progressively increasing in size

The lesion was painless, with no inflammatory signs and no evidence of trauma. It was evolving in a context of apyrexia and preservation of general condition. The patient initially consulted a family doctor, where he underwent a biopsy. Histological analysis of the biopsy material revealed epithelial proliferation throughout the entire epithelial thickness, characterized by cytoarchitectural disorganization over the entire height of the epithelium, with an anarchic arrangement of keratinocytes (figure 2).

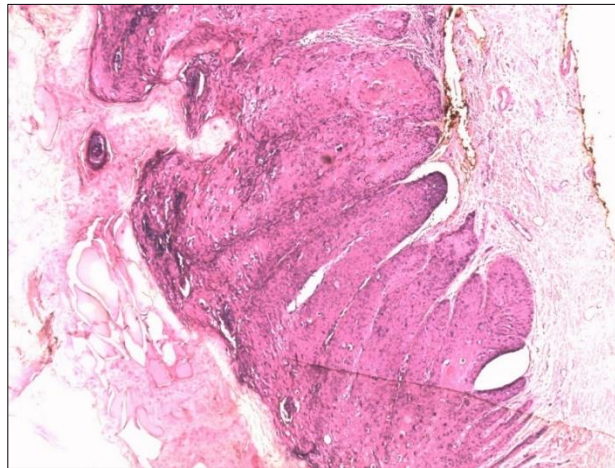


Figure 2 Squamous cell carcinoma of the nail. Epithelial proliferation involving the entire epithelial thickness, characterized by cytoarchitectural disorganization throughout its height, with an anarchic arrangement of keratinocytes.

The latter showed marked staged cytonuclear atypia with anisocytosis, anisokaryosis, nuclear hyperchromatism, some nuclear monstrosities and multinucleations, staged mitoses and a few scattered dyskeratotic cells (figure 3).

The overall picture was consistent with Bowen's disease squamous cell carcinoma in situ involving the nail bed epithelium and adjacent epidermis. He was then referred to us for further treatment. Negative mycological examination of the nail plate ruled out onychomycosis. PCR detection of the HPV virus was also negative. Blood analysis revealed no abnormalities. On physical examination, no lymphadenopathy was observed, and radiography of the affected finger revealed no bone involvement (figure 4).

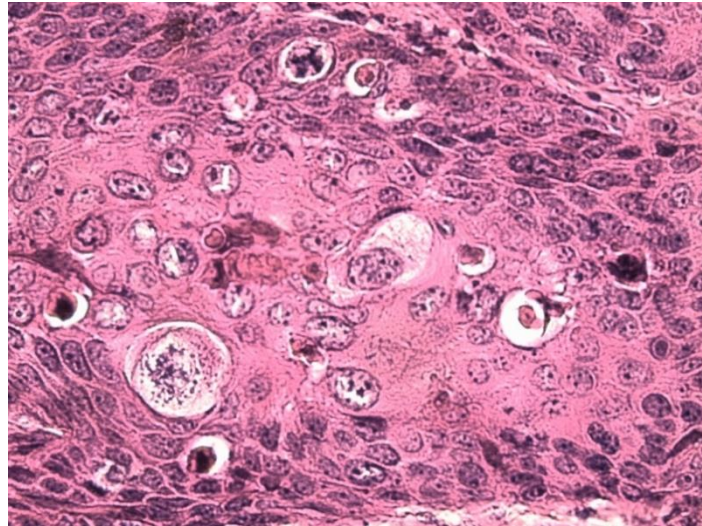


Figure 3 Squamous cell carcinoma of the nail. Marked staged cytonuclear atypia with anisocytosis, anisokaryosis, nuclear hyperchromatism, some nuclear monstrosities and multinucleations mitoses and a few scattered dyskeratotic cells

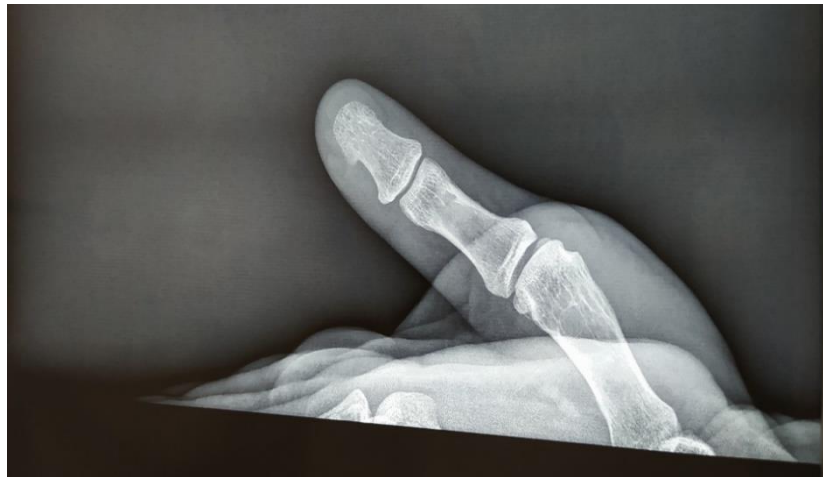

Figure 4 Absence of bone lysis on hand radiography.

Furthermore, the patient denied any history of exposure to radiation, chemicals or repeated trauma to the affected finger. The patient underwent surgical excision using Mohs micrographic surgery. After partial avulsion of the nail plate, a poorly delineated erosion approximately 5 mm in diameter was visible within the distal part of the lateral nail fold (Figure 5). Postoperatively, the patient noticed a sensation of hypoesthesia in the treated area, which regressed almost completely over the following months.

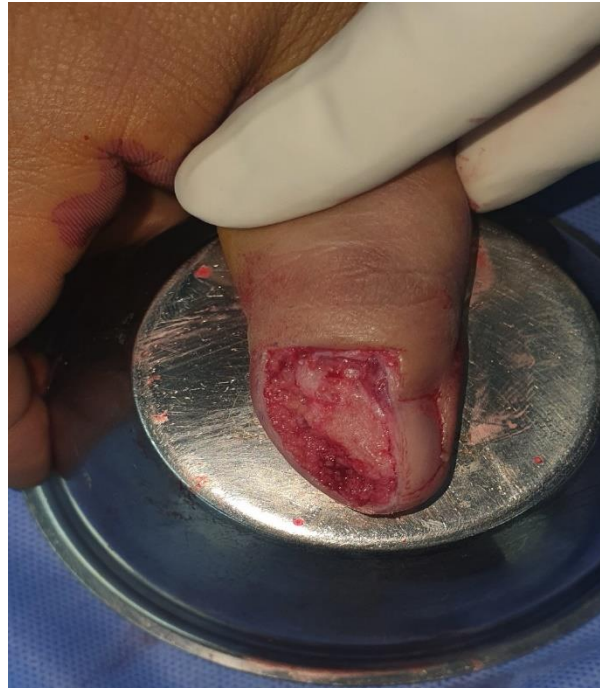

Figure 5 Result after surgical excision using Mohs micrographic surgery

3. Discussion

Bowen's disease and invasive squamous cell carcinoma are the most common neoplasms affecting the nail [4,5]. It is often misdiagnosed because of its benign appearance and slow progression. The clinical picture of this disease is not uniform and can mimic a number of other dermatological disorders, such as vulgar warts, onychomycosis, nail dystrophy, paronychia, eczema, pyogenic granuloma, verrucous tuberculosis or malignant melanoma [6,7]. Consequently, a biopsy of any chronic nail tissue lesion is essential. Various studies have attributed an etiological role to HPV, in particular HPV-16, in the development of these nail tissue neoplasms [8,5]. A number of predisposing factors have also been identified, including radiotherapy, exposure to X-rays, arsenic ingestion and trauma [8]. The incidence of metastasis of these tumours is low, and lymph node involvement is reported in only 2% of cases of subungual squamous cell carcinoma [9]. However, once metastasized, the disease can be fatal [10]. Staging is necessary for proper treatment of nail tumours [4]. Stage I represents localized disease, as in Bowen's disease, while stages II and III represent lymph node and distant metastases respectively. Preoperative assessment should include a physical examination for adenopathy and radiographic examination of the whole hand for bone involvement [9]. Mohs micrographic surgery is the treatment of choice for Bowen's disease or squamous cell carcinoma of nail tissue without bone involvement [4,5,11]. The nail is a difficult site for Mohs micrographic surgery due to its unique anatomical and histological features [12]. Cure rates of over 92% have been reported with this surgical approach [9]. For tumors with bone involvement, amputation is preferable [4].

4. Conclusion

Bowen's disease of the should be considered in the presence of any treatment-resistant nail lesion. Any chronic nail lesion should be biopsied. The treatment of choice for nail Bowen's disease is Mohs surgery. Follow-up is recommended, as relapses may occur 2-3 years after primary surgery.

Compliance with ethical standards

Disclosure of conflict of interest

No conflict of interest to be disclosed.

Statement of informed consent

Informed consent was obtained from all individual participants included in the study.

References

- [1] Morton C, Birnie A, Eedy D. British association of dermatologists : guidelines for the management of squamous cell carcinoma in situ (bowen’s disease). *Br j dermatol*. 2014;170:245–60.
- [2] Sau P, McMartin SL, Sperling LC, Katz R: Bowen’s disease of the nail bed and periungual area. *Arch Dermatol*. 1994;130:204–209.
- [3] LECERF P, RICHERT B, ANDRÉ J. Le carcinome épidermoïde de l’appareil unguéal. In : *Annales de dermatologie et de vénéréologie*. Masson, 2014. p. 156-160.
- [4] Goldminz D, Bennett RG: Mohs micrographic surgery of the nail unit. *J Dermatol Surg Oncol* 1992;18:721–726.
- [5] Zaiac MN, Weiss E: Mohs micrographic surgery of the nail unit and squamous cell carcinoma. *Dermatol Surg* 2001;27:246–251.
- [6] Baran R, Simon Cl: Longitudinal melanonychia: A symptom of Bowen’s disease. *J Am Acad Dermatol* 1988;18:1359–1360
- [7] Saijo S, Kato T, Tagami H: Pigmented nail streaks associated with Bowen’s disease of the nail matrix. *Dermatologica* 1990;181:156–158
- [8] Krull EA: Epidermoid carcinoma of the subungual and periungual tissues; in Krull E, Zook EG, Baran R, Haneke E (eds): *Nail Surgery: A Text and Atlas*. Philadelphia, Lippincott, Williams & Wilkins, 2001, pp 297–304.
- [9] Ongenaes K, Van de kerckhove M, Naeyaert JM. Bowen’s disease of the nail. *Dermatology*, 2002, vol. 204, no 4, p. 348-350.
- [10] kouskousis CE, Scher RK, Kopf AW: Squamous cell carcinoma of the nail bed. *J Dermatol Surg Oncol* 1982;8:853–855.
- [11] Baran R, Dupré A, Sayag J, Letessier S, Robins P, Bureau H: Maladie de Bowen de l’appareil unguéal (5 cas) avec revue de la littérature (20 cas). *Ann Dermatol Vénéréol* 1979;105:227– 233.
- [12] Fleckman P, Allan C: Surgical anatomy of the nail unit. *Dermatol Surg* 2001;27:257–260